

Precision and innovation: Carbon dioxide laser excision of ranula

Pankaj Goyal¹, Kishan Kumawat¹, Manisha Chouhan², Chandrani Chatterjee³ & Nirupama Kothari⁴

¹ Consultant ENT Surgeon, Apollo E.N.T. Hospital, Pal Road, Jodhpur, Rajasthan, India

² Consultant Radiologist, Medipulse Hospital, Jodhpur, Rajasthan, India

³ E.N.T. Department, AIIMS, Patna, India

⁴ Consultant Pathologist, Sterling Accuris Diagnostics, Jodhpur, Rajasthan, India

Correspondence: Pankaj Goyal, Consultant ENT surgeon, Apollo E.N.T. Hospital, Pal Road, Jodhpur, Rajasthan, India. E-mail: pank1414@gmail.com

Received: June 02, 2024

DOI: 10.14295/bjs.v3i9.640

Accepted: July 22, 2024

URL: <https://doi.org/10.14295/bjs.v3i9.640>

Abstract

A ranula is a relatively uncommon condition characterized by the formation of a mucus-filled cyst within the floor of the mouth. This benign lesion typically originates from a blocked or damaged sublingual salivary gland duct, accumulating saliva in a localized cyst-like structure. Aspiration of cystic fluid, sclerotherapy, marsupialization, incision and drainage, excision of the ranula alone, excision of the sublingual gland with or without ranula, laser excision, and ranula vaporization are just a few of the suggested therapies for ranula. The outcomes of the varied treatments have been inconsistent. Most surgeons concur that the sublingual gland must be removed from the ranula. The authors provide a case report on carbon dioxide laser treatment for ranula, as well as a literature review. According to the authors' experience and literature, carbon dioxide laser excision of ranula is a safe procedure with minimum recurrence.

Keywords: mucocele, sublingual gland, floor of mouth, carbon dioxide laser, surgical excision.

Precisão e inovação: Excisão de rânula com laser de dióxido de carbono

Resumo

A rânula é uma condição relativamente incomum caracterizada pela formação de um cisto cheio de muco no assoalho da boca. Esta lesão benigna normalmente se origina de um ducto da glândula salivar sublingual bloqueado ou danificado, acumulando saliva em uma estrutura localizada semelhante a um cisto. Aspiração de líquido cístico, escleroterapia, marsupialização, incisão e drenagem, excisão isolada da rânula, excisão da glândula sublingual com ou sem rânula, excisão a laser e vaporização da rânula são apenas algumas das terapias sugeridas para a rânula. Os resultados dos diversos tratamentos têm sido inconsistentes. A maioria dos cirurgiões concorda que a glândula sublingual deve ser removida da rânula. Os autores fornecem um relato de caso sobre tratamento com laser de dióxido de carbono para rânula, bem como uma revisão da literatura. De acordo com a experiência e a literatura dos autores, a excisão da rânula com laser de dióxido de carbono é um procedimento seguro e com recorrência mínima.

Palavras-chave: mucocele, glândula sublingual, assoalho da boca, laser de dióxido de carbono, excisão cirúrgica.

1. Introduction

Lesions of the salivary glands may present as intraoral masses, cervical masses, or both. Ranulas, which are classed as mucus extravasation incidents, are often induced by trauma to the sublingual gland or an obstruction of its ducts, resulting in mucus retention. The sublingual gland, located below the tongue, is responsible for saliva production. When its ducts become obstructed or injured, saliva or mucus accumulates, causing a cystic swelling known as a ranula (Morton, 2018). The most common appearance of a ranula is a transparent swelling on the floor of the oral cavity.

Ranulas are categorized in literature as simple (intraoral) if they are limited to the oral cavity; and plunging

(cervical) if they extend beyond the mylohyoid owing to a congenital dehiscence in the mylohyoid or between the mylohyoid and hyoglossus along the deep lobe of the submandibular gland (Yang; Hong, 2014). External trauma, eating, or orthodontic treatment can cause the sublingual duct to burst or become blocked (Harrison, 2010; Morton, 2018). The Latin rana, which means frog, is the source of the phrase ranula, which refers to a small frog resembling a bulging frog's underbelly (Crusdale et al., 1988).

Hippocrates explained that ranula resulted from persistent inflammation, Pare believed that ranula symbolized the pituitary and brain's descent, and W. Boyd explained that ranula was a dilatation of the submandibular gland's duct (Golden et al., 2016). Suzanne (1887) and von Hippel et al. (1897), first documented the sublingual gland origin of ranulas toward the end of the nineteenth century. The body of the sublingual gland, the ducts of Rivinus of the sublingual gland, and occasionally the minor salivary glands at this site are the origins of the ranula (Suzanne, 1887).

Nonetheless, Thompson rejected an embryologic etiology in 1920 and disregarded the sublingual gland's function in the development of ranulas. He thought that, like brachial cysts, ranulas are formed from the remains of the brachial arches (Thompson, 1920). Bhaskar et al. (1956) came to the conclusion in 1956 that ranulas are lined by connective tissue without epithelium and are created when saliva leaks from injured salivary ducts. The primary salivary glands each have a distinct propensity to develop particular disease patterns: pleomorphic adenomas are found in the parotid gland, sialolithiasis is found in the submandibular gland, and sublingual ranulas are found in the sublingual gland (Curtin, 2007).

Excretory duct rupture is the first step in the creation of ranulas, which is then followed by saliva extravasation and deposition into the surrounding tissue (Bronstein; Clark, 1984). This mucus creates a pseudocyst without an epithelial lining when it builds up in the surrounding connective tissues (Morton; Bartley, 1995). The management of ranulas is a contentious issue, with conflicting data regarding the most effective therapeutic approach because of the present understanding of the aetiopathogenesis of the condition. The literature contains references to a wide range of surgical techniques, from straightforward aspiration to whole or partial excision of the ranula and/or the sublingual salivary gland, occasionally including the submandibular salivary gland. Among these are LASER ablation, hydro-dissection, cryotherapy, sclerotherapy, marsupialization, and dissection.

Depending on the procedure used, the recurrence rate differs (Patel et al., 2009). Due to the inherent properties of CO₂ laser therapy, it is recommended, particularly when considering the advantages for the patient, which include reduced edema and postoperative pain, no hemorrhagic episodes, and a satisfactory outcome from an aesthetic and functional standpoint (Niccoli-Filho; Morosolli, 2003).

2. Case report

A thirty-two-year-old female patient arrived at Apollo E.N.T. hospital, Jodhpur, Rajasthan, India, complaining of a swelling under her tongue on her left side that was gradually getting larger. She said eating some meals caused her difficulty, but overall, the swelling was innocuous. Over the previous three months, the bulge gradually grew larger from its initial small appearance.

Six months prior, she had an intraoral sialolith extracted. There was no prior medical history of gum bleeding, odynophagia, fever, or recurrent sore throats. There were no comorbidities, and she denied having an addiction. Upon clinical examination, a 2 cm round, fluctuant, and translucent swelling was observed on the floor of the mouth on the left side, adjacent to the lateral border of the tongue (Figure 1).

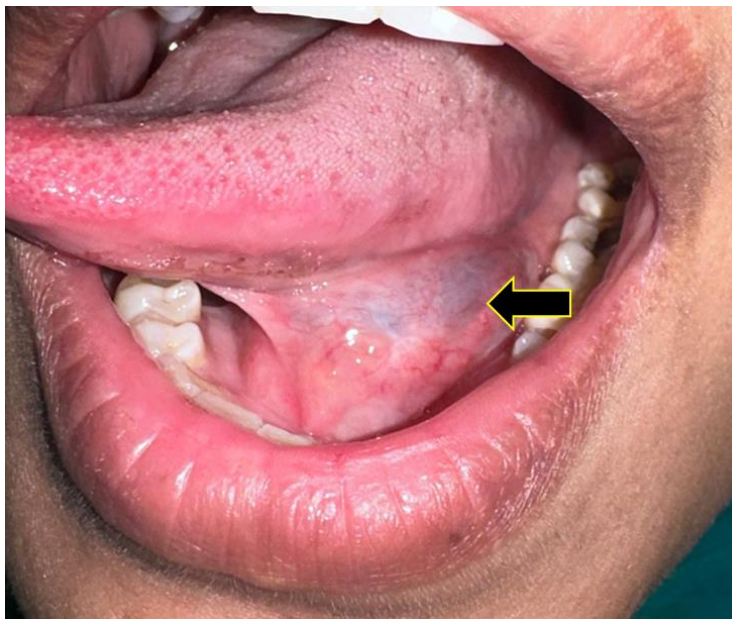

Figure 1. The clinical picture of oral ranula – a typical submucosal bluish, dome-shaped ranula. Source: Authors, 2024.

The swelling was non-tender to palpation and could be compressed with mild pressure. The overlying mucosa appeared intact without any signs of inflammation or ulceration. The swelling was brilliant transilluminant (Figure 2). There was no palpable lymphadenopathy in the neck. Upon further inspection, the ranula was noted to be mobile upon palpation, suggestive of a superficial location relative to deeper structures such as the mylohyoid muscle. The patient reported intermittent episodes of increased size of swelling after meals, correlating with increased salivary flow. Based on clinical findings, a provisional diagnosis of intraoral ranula was made.

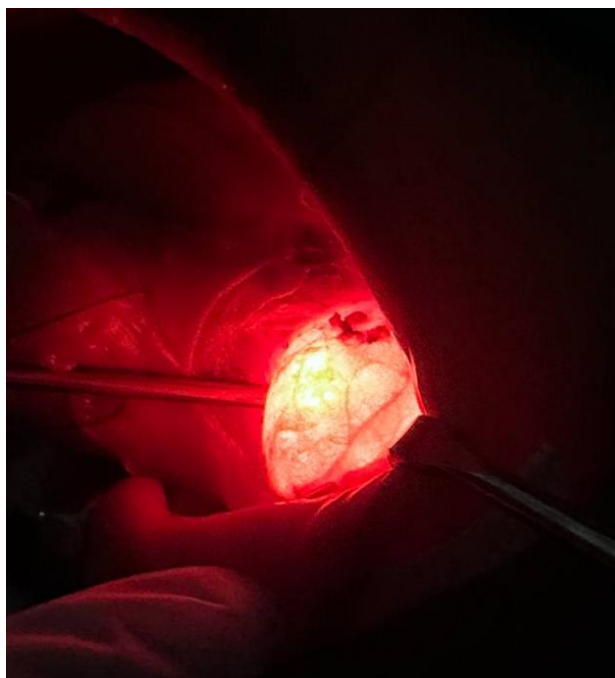


Figure 2. Intra-oral Ranula was brilliantly enhanced during transillumination. Source: Authors, 2024.

To confirm the diagnosis and assess the extent of the lesion, magnetic resonance imaging (MRI) was advised.

The swelling was located in the left sublingual region. It measured approximately 2.5 cm in diameter. The lesion appeared as a well-defined, round cystic structure with homogeneous high signal intensity on T2-weighted images, consistent with fluid content typical of a mucous retention cyst (ranula) (Figure 3). The ranula was observed to be superficial to the mylohyoid muscle and did not extend into deeper structures of the floor of the mouth or involve the lingual nerve. After discussion of treatment options, the patient opted for Carbon dioxide Laser assisted surgical excision of the ranula. The procedure was performed under general anesthesia.

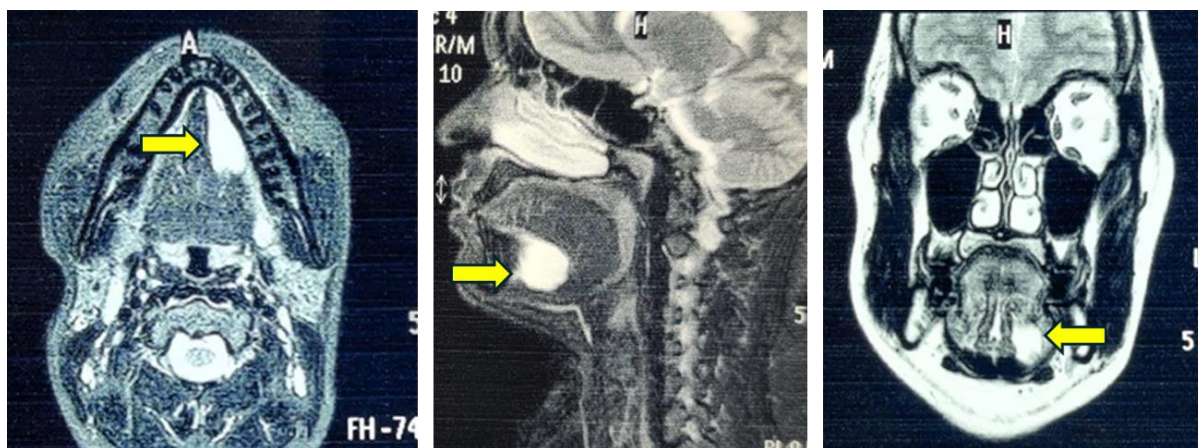


Figure 3. Contrast-enhanced magnetic resonance imaging showed the lesion appeared as a well-defined, round cystic structure with homogeneous high signal intensity on T2-weighted images, consistent with fluid content typical of a mucous retention cyst (ranula). Source: Authors, 2024.

After careful surgical planning, general anesthesia was induced. The dome is grasped with forceps and continuous CO₂ laser radiation was used to first outline the periphery of the lesion in continuous mode with 4 watts of power density, 0.8 mm focus with constant vacuum removal of the smoke plume to excise the dome (Figure 4). The marsupialization was done with laser vaporization of the base of the ranula and the internal epithelium of the lesion. No suturing was necessary.

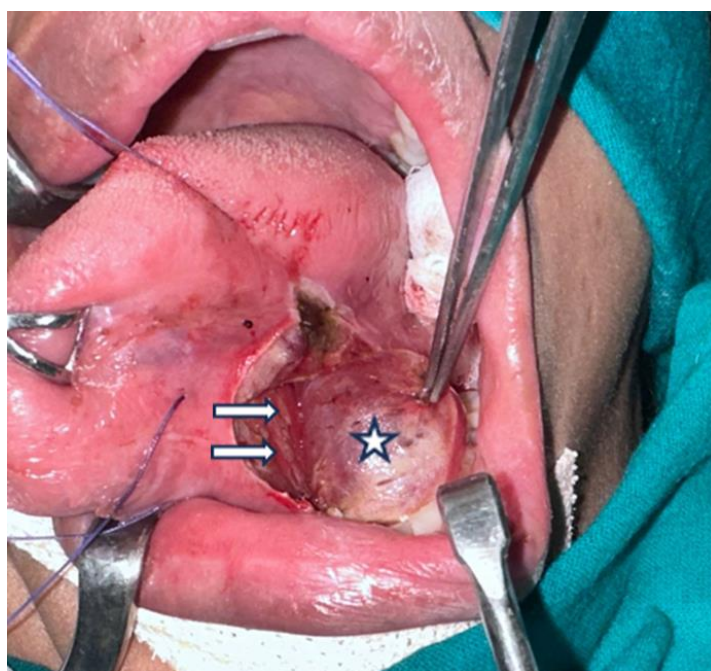


Figure 4. Intraoperative picture of ranula (*star mark) separating from mylohyoid muscle fibres (small white arrow mark) after unroofing the dome with CO₂ Laser. Source: Authors, 2024.

The patient, as well the surgeon and team, were protected with laser safety glasses and masks. Intact removed tissue specimens were forwarded for anatomical and histopathological examination that confirmed our diagnosis (Figure 5).

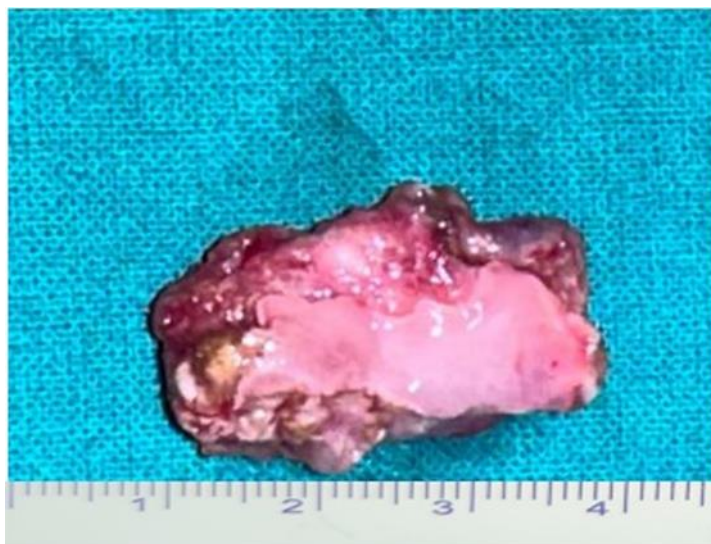

Figure 5. Surgical specimen. Source: Authors, 2024.

Histopathological examination of the excised specimen confirmed the diagnosis of a mucous retention cyst consistent with a ranula. The lining epithelium showed typical features of squamous epithelium with underlying fibrovascular connective tissue (Figure 6). The postoperative period was uneventful, with minimal pain managed effectively with analgesics. The patient resumed a normal diet within 24 h post-surgery. No signs of recurrence were noted during follow-up appointments at 1 week, 1 month, and 3 months post-surgery.

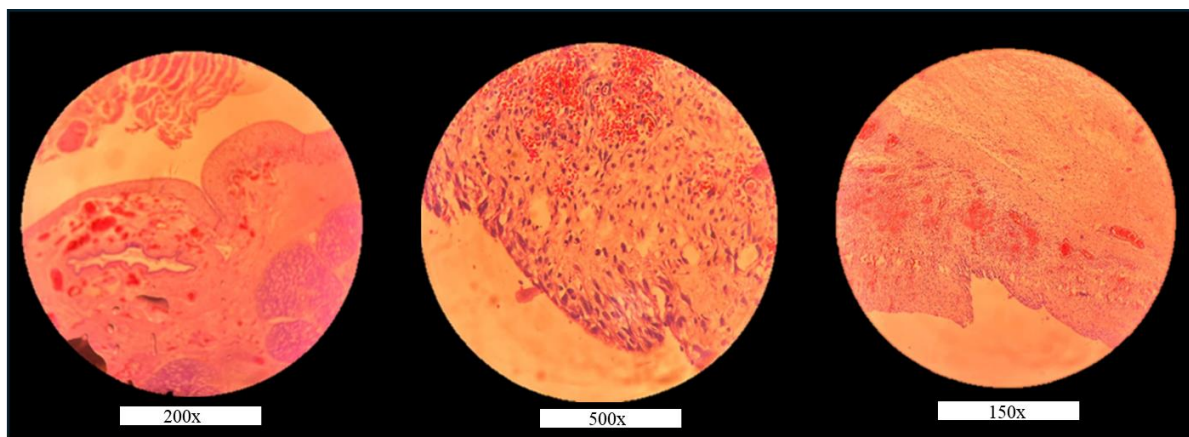


Figure 6. Histopathological slides of ranula. Source: Authors, 2024.

3. Discussion

The only major salivary gland that is not enclosed is the sublingual gland, which is also the smallest. The floor of the mouth mucosa superiorly, the mylohyoid muscle inferiorly, the mandible laterally, the genioglossus muscle medially, and the submandibular gland posteriorly bind each of the paired almond-shaped glands. The sublingual glands lack posterior fascial boundaries, which means that lesions originating from the gland may migrate to the submandibular and parapharyngeal areas. Five to fifteen minor excretory ducts, also known as Rivinus ducts, drain each gland. These ducts transport saliva into the oral cavity through tiny mucosal folds called plica sublingualis on the floor of the mouth. The ducts occasionally combine to form a bigger duct known as the

Bartholin duct, which empties into the submandibular duct and exits through the sublingual caruncle. The sublingual glands are supplied by branches of the face and lingual arteries. Ten percent of the saliva produced in the oral cavity is produced by the sublingual glands, which continuously secrete a highly proteinaceous, inconsistent flow of saliva.

An obstruction or disturbance of the sublingual duct causes a ranula. The most common cause of intraoral ranulas is obstruction of the salivary duct, which leads to the development of a mucous retention cyst. A mucus collection that extravasates into nearby tissue and triggers an inflammatory response that walls off the mucus collection are usually the source of plunging ranulas. It does not have a true epithelial lining, making it a pseudocyst. It is believed that mucus accumulates and leaks out as a result of sublingual duct obstruction, duct damage, or ruptured acini, which are caused by immunologic abnormalities, sialolith formation, congenital anomalies, direct trauma, and, in rare cases, tumors (Morton; Ahmad, 2010).

The second and third decades of life are when ranulas most frequently occur, yet examples have been reported in people as young as 3 to 61 years old. A modest 1.3:1 female-to-male predominance is present. Simple ranulas typically manifest as fluctuant swelling on the floor of the mouth that makes it bothersome or impairs speech. Eating or swallowing does not affect the size or position.

Plunging ranulas are variable cystic neck masses that typically appear in the submandibular area, while they can also occur in the mediastinum, lower neck, ipsilateral, or bilateral parapharyngeal and retropharyngeal spaces (Langlois; Kolhe, 1992; Davison et al., 1998). In at least 20% of cases, plunging ranulas might manifest without a clear intraoral component. Trauma, previous salivary gland infection, and submandibular surgery are risk factors for the development of ranula.

4. Diagnosis

The assessment of intraoral and cervical masses begins with a thorough history and physical examination. Assessing and examining the floor of the mouth for a fluctuating swelling, frequently with a bluish tint, can help determine whether or not a patient has ranulas. Imaging is a useful tool for both surgical planning and diagnosis (White et al., 2001; Koch et al., 2022).

A contrast agent can be used in computed tomography and MRI to help differentiate ranulas from other floor of the mouth lesions. Determining the ranula's relationship to nearby structures can also be done with imaging, especially when the ranula is plunging. MRI is a valuable imaging modality in the evaluation of ranulas due to its ability to provide detailed soft tissue characterization and delineation of anatomical relationships (Vogl et al., 1993; Tavit et al., 1995; Turetschek et al., 1995; Rosen et al., 1998). Ranulas show up bright on T2-weighted MRI images with well-defined borders. It helps differentiate ranulas from other lesions such as cystic hygromas or neoplastic masses by demonstrating typical fluid signal intensity and lack of enhancement.

Dermoid, lymphatic malformations, and foregut duplication cysts are among the differential diagnoses for an intraoral ranula. A plunging ranula can have a wider differential diagnosis, which includes solid neck masses such as lipomas, dermoid, submandibular gland neoplasms, and lymphadenopathy, as well as thyroglossal duct cysts, epidermoid cysts, laryngoceles, and lymphatic or vascular malformations. Intraoral ranulas can vary in size and presentation, and their management depends on the size of the lesion, symptoms, and patient preference.

Treatment options for ranulas include a range of surgical and medicinal procedures such as bleomycin (OK-432) sclerotherapy, incision and drainage, marsupialization, and cyst excision via intraoral, transcervical, or dual methods, with or without the removal of the sublingual gland (Rho et al., 2006). Patel et al. (1990) pioneered the continuous wave carbon dioxide laser technology in 1964 (Asnaashari; Zadsirjan, 2014).

Due to a number of features that make it perfect for intraoral soft tissue surgery, the carbon dioxide laser has since been used more frequently in the field of oral and maxillofacial surgery (Frame, 1985; Asnaashari et al., 2011). Since water is its chromophore, it is highly absorbed by the oral mucosal tissues with high water content. When intracellular water absorbs the carbon dioxide laser, it causes a photothermal effect that is exhibited by cellular rupture and vaporization.

A zone of lateral thermal injury is produced when heat is produced and transferred into the tissues around it. Hemostasis is the clinical manifestation of this zone of lateral thermal injury, which causes blood vessels up to 500 μ m in diameter to coagulate. Patients who receive laser treatment experience reduced pain, edema, and scarring (Frame, 1985; Asnaashari et al., 2011). Nine ranulas were evaporated in 1985 by Frame (1986), and nine ranulas were treated in 1991 by Barak et al. (1991) Sheldon et al. (1994) used two distinct laser procedures to evaporate eight ranulas: one involved vaporizing the lesion with a defocused beam, while the other involved

vaporizing the base and wall of the lesion together with focused beam excision of the dome. Within six months, he reported no issues and no recurrence.

There are various benefits to treating ranula with a carbon dioxide laser in the oral cavity. It cuts tissue precisely and does not harm nearby non-target tissue too much. It is the surgeon's perception of "precision" depth that makes the difference between the scalpel and the laser. The tissue vaporizes when it absorbs the laser energy without contacting it. In addition, the zones of necrosis and thermal damage beneath the entire incision are not deeper than 0.5 mm, and the laser energy only penetrates 0.1 mm beyond the cut (Gáspár et al., 1990; Pogel et al., 1990).

The risk of harming the lingual nerve and submandibular duct is decreased because of the laser's precise depth of penetration (Catone, 1997). By ablation of the ranula wall in the defocused mode, where the laser energy penetration is even shorter, the risk to the lingual nerve and submandibular duct is substantially reduced. Additionally, operational haemorrhage is reduced, and small blood vessels coagulate effectively. This is crucial for surgery on the highly vascular floor of the mouth. The lesion can be seen for ablation on the wall and base when using the carbon dioxide laser to maintain a "bloodless" surgical site and outline the lesion without breaking through the roof. Reduced operational hemorrhage gives the surgeon a clear view of the surgical site and lowers the risk of damaging crucial anatomical structures like the lingual nerve and submandibular duct (Basu et al., 1988; Niccoli-Filho; Morosolli, 2003).

This is aptly illustrated in the case study that follows, where the lesion's wall and base may be fully visible for ablation, including posteriorly positioned ranulas and the dome was clearly defined. There is a reduction in bacteremia and immediate sterilization of the surgical site. Additionally, close contact with surgical equipment like the scalpel causes less mechanical stress to the tissue. Due to the exceptional friability and mobility of the mucosa in this area, this is helpful for ranula therapy and floor-of-the-mouth surgery. Any instrument applied to the area could cause needless trauma.

The patient can resume oral intake as soon as feasible with minimal difficulty because of the laser's minimal postoperative pain. Although reduced scarring is linked to laser use, this is significant for maintaining normal tongue movement during speech and swallowing on the floor of the mouth (Fisher; Frame, 1984; Duncavage; Ossoff, 1986). The function and mobility of the tongue are affected by scarring over the area. Additionally, the base of the lesion can be vaporized with the laser, sealing the tiny salivary glands underneath and gradually eliminating the cells. This lessens the chance of recurrence, negating the need to remove the sublingual glands.

There has been no reported negative impact on salivary flow after laser transection, according to Fisher and Frame (Gáspár; Szabo, 1990; Barak et al., 1991). According to Gaspar & Szabo (1990), none of them displayed signs of impaired salivary function or ductal constriction. Following healing, neither clinical evidence of ductal stenosis nor mucosal contraction surrounding the ducts was observed in our postoperative outcome.

On the other hand, increased tissue loss, a lack of specimens for microscopic examination, and frequent severe postoperative edema are associated with cryosurgery (Pogel et al., 1990; Catone, 1997). Increased postoperative scar contracture and discomfort are associated with tissue coagulation and destruction caused by electrosurgery (Pogel et al., 1990; Catone, 1997). Therefore, ablation of the intraoral ranula using the CO₂ laser is advised, either in pure vaporization or mixed excision-vaporization mode.

5. Conclusions

In summary, carbon dioxide laser therapy is an important, beneficial, and alternate therapeutic option for ranula. Its ease of use, accuracy in cutting and coagulation depth, and decreased surgical bleeding. Both the incidence of postoperative pain and scarring have been lowered, surpassing the results of standard scalpel treatment. Laser treatment has decreased the recurrence of ranula by vaporizing the base of the gland and closing the minor salivary glands and ducts. This has eliminated the need to remove the sublingual gland, reducing the risk of surgical complications. This case highlights the importance of prompt diagnosis and appropriate management of intraoral ranulas to alleviate symptoms and prevent complications.

6. Acknowledgments

We would like to acknowledge the patient for providing consent for the publication of this case report.

7. Authors' Contributions

Pankaj Goyal, Kishan Kumawat, Manisha Chouhan, Chandrani Chatterjee, Nirupama Kothari: All authors contributed to the conception, drafting, and critical revision of the manuscript. All authors have approved the final version of the manuscript for submission.

8. Conflicts of Interest

No conflicts of interest.

9. Ethics Approval

Yes, applicable. Written informed consent was obtained from the patient for the publication of this case report and any accompanying images.

10. References

- Abdul-Aziz, D., & Adil, E. (2015). Ranula excision. *Operative Techniques in Otolaryngology – Head and Neck Surgery*, 26(1), 21-27. <https://doi.org/10.1016/j.otot.2015.01.005>
- Asnaashari, M., Mohebi, S., & Paymanpour, P. (2011). Pain reduction using low level laser irradiation in single-visit endodontic treatment. *Journal of Lasers in Medicinal Sciences*, 2(04), 139-143.
- Asnaashari, M., & Zadsirjan, S. (2014). Application of laser in oral surgery. *Journal of Lasers in Medicinal Sciences*, 5(03), 97-107. <https://pubmed.ncbi.nlm.nih.gov/25653807>
- Barak, S., Horowitz, I., Katz, J., & Kaplan, I. (1991). Experiences with the CO₂ laser in the surgical treatment of intra-oral salivary gland pathology. *Journal of Clinical Laser Medicine & Surgery*, 9(4), 297. <https://doi.org/10.1089/clm.1991.9.295>
- Basu, M. K., Frame, J. W., & Rhys, P. H. (1988). Wound healing following partial glossectomy using the CO₂ laser, diathermy and scalpel: a histological study in rats. *The Journal of Laryngology and Otology*, 102(4), 322-327. <https://doi.org/10.1017/S0022215100104852>
- Bhaskar, S. N., Bolden, T. E., & Weinmann, J. P. (1956). Pathogenesis of mucocoeles. *Journal of Dental Research*, 35(06), 863-874. <https://doi.org/10.1177/00220345560350060601>
- Bronstein, S. L., & Clark, M. S. (1984). Sublingual gland salivary fistula and sialocele. *Oral Surgery, Oral Medicine, Oral Pathology*, 57(4), 357-361. [https://doi.org/10.1016/0030-4220\(84\)90149-X](https://doi.org/10.1016/0030-4220(84)90149-X)
- Catone, G. A. (1997). Laser applications in oral and maxillofacial surgery. Saunders, W. B., Philadelphia, 307 p.
- Crysdale, W. S., Mendelsohn, J. D., & Conley, S. (1988). Ranulas–mucocoeles of the oral cavity: experience in 26 children. *The Laryngoscope*, 98(3), 296-298. <https://doi.org/10.1288/00005537-198803000-00011>
- Curtin, H. D. (2007). Imaging of the Salivary gland. In: Myers Eugene, N., Ferris Robert, L. (eds) Myers' salivary gland disorders. Springer, Berlin, 17-31 p.
- Davison, M. J., Morton, R. P., McIvor, N. P. (1998). Plunging ranula: Clinical observations. *Journal of the Sciences and Specialties of the Head Neck*, 20(1), 63-68. [https://doi.org/10.1002/\(SICI\)1097-0347\(199801\)20:1%3C63::AID-HED10%3E3.0.CO;2-Q](https://doi.org/10.1002/(SICI)1097-0347(199801)20:1%3C63::AID-HED10%3E3.0.CO;2-Q)
- Duncavage, J. A., & Ossoff, R. H. (1986). Use of the CO₂ laser for malignant disease of the oral cavity. *Laser in Surgery and Medicine*, 6(5), 442-444. <https://doi.org/10.1002/lsm.1900060504>
- Fisher, S. E., & Frame, J. W. (1984). The effect of the CO₂ surgical laser on oral tissues. *British Journal of Oral and Maxillofacial Surgery*, 22(6), 414-418. [https://doi.org/10.1016/0266-4356\(84\)90048-2](https://doi.org/10.1016/0266-4356(84)90048-2)
- Frame, J. W. (1985). Removal of soft tissue pathology with the CO₂ laser. *Journal of Oral and Maxillofacial Surgery*, 43(11), 850-855. [https://doi.org/10.1016/0278-2391\(85\)90221-6](https://doi.org/10.1016/0278-2391(85)90221-6)
- Gáspár, L., & Szabo, G. (1990). Manifestations of the advantages and disadvantages of using the CO₂ laser in oral surgery. *Journal of Clinical Laser Medicine & Surgery*, 8(1), 39-43. PMID: 10148946
- Gáspár, L., Sudár, F., Tóth, J., & Madarász, B. (2009). Oral lesions induced by scalpel. electrocautery, and CO₂ laser compared with light. scanning and electron microscopy. *Journal of Clinical Laser Medicine & Surgery*, 9(5), 349. <https://doi.org/10.1089/clm.1991.9.349>
- Golden, B., Drake, A. F., & Talavera, F., & Roland, P. S. (2016). Ranulas and plunging ranulas. Medscape Last

- updated March 28. Available in: <https://emedicine.medscape.com/article/847589-overview> Access in: July 20, 2024
- Gontarz, M., Bargiel, J., Gąsiorowski, K., Marecik, T., Szczurowski, P., Zapała, J., Gałązka, K., & Wyszynska-Pawelec, G. (2023). Surgical treatment of sublingual gland ranulas. *International Archives of Otorhinolaryngology*, 27(2), e296-e301. <https://doi.org/10.1055/s-0042-1744166>
- Harrison, J. D. (2010). Modern management and pathophysiology of ranula: Literature review. *Journal of the Sciences and Specialties of the Head Neck*, 32(10), 1310-1320. <https://doi.org/10.1002/hed.21326>
- Koch, M., Mantsopoulos, K., Leibl, V., Müller, S., Iro, H., & Sievert, M. (2022). Ultrasound in the diagnosis and differential diagnosis of enoral and plunging ranula: a detailed and comparative analysis. *Journal of Ultrasound*, 26(2), 487-495. <https://doi.org/10.1007/s40477-022-00743-7>
- Kolong, D., Iduh, A., Chukwu, I., Mugu, J., Nhu, S., & Augustine, S. (2017). Ranula: Current concept of pathophysiologic basis and surgical management options. *World Journal of Surgery*, 41, 1476-1481. <https://doi.org/10.1007/s00268-017-3901-2>
- Langlois, N. E., & Kolhe, P. (1992). Plunging ranula - A case report and a literature review. *Human Pathology*, 23(11), 1306-1308. [https://doi.org/10.1016/0046-8177\(92\)90300-R](https://doi.org/10.1016/0046-8177(92)90300-R)
- Morton, R. P., & Bartley, J. R. (1995) Simple sublingual ranulas: pathogenesis and management. *Journal of Otolaryngology*, 24(4), 253-254. PMID: 8551539
- Morton, R. P., Ahmad, Z., & Jain, P. (2010). Plunging ranula: congenital or acquired? *Otolaryngology Head Neck Surgery*, 142(1), 104-107. <https://doi.org/10.1016/j.otohns.2009.10.014>
- Morton, R. P. (2018). Surgical management of ranula revisited. *World Journal of Surgery*, 42, 3062-3063. <https://doi.org/10.1007/s00268-018-4666-y>
- Niccoli-Filho, W., & Morosolli, A. R. C. (2003). CO₂ laser treatment of actinic cheilitis associated with squamous-cell carcinoma of lower lip. *Journal of Oral Laser Applications*, 3(4), 251-253.
- Patel, M. R., Deal, A. M., & Shockley, W. W. (2009) Oral and plunging ranulas: what is the most effective treatment? *Laryngoscope*, 119(8), 1501-1509. <https://doi.org/10.1002/lary.20291>
- Pogel, M. A., McCracken, K. J., & Daniels, T. E. (1990). Histologic evaluation of the width of soft tissue necrosis adjacent to carbon dioxide laser incisions. *Oral Surgery, Oral Medicine, Oral Pathology*, 70(5), 564-568. [https://doi.org/10.1016/0030-4220\(90\)90397-B](https://doi.org/10.1016/0030-4220(90)90397-B)
- Rho, M. H., Kim, D. W., Kwon, J. S., (2006). OK-432 sclerotherapy of plunging ranula in 21 patients: It can be a substitute for surgery. *American Journal of Neuroradiology*, 27(5), 1090-1095. <https://www.ajnr.org/content/27/5/1090.short>
- Rosen, D., Wirtschafter, A., Rao, V. M., Wilcox, T. O. (1998). Dermoid cyst of the lateral neck: A case report and literature review. *Ear, Nose & Throat Journal*, 77(125), 129-132. <https://doi.org/10.1177/014556139807700212>
- Sheldon, M., Shlomo, B., & Isack, H. (1994). Carbon dioxide laser excision and vaporization of nonplunging ranulas: A comparison of two treatment protocols. *Journal of Oral and Maxillofacial Surgery*, 52(4), 370-372. [https://doi.org/10.1016/0278-2391\(94\)90439-1](https://doi.org/10.1016/0278-2391(94)90439-1)
- Suzanne, G. (1887). Recherches anatomiques sur le plancher de la bouche, avec études anatomique et pathogenique sur la grenouillette commune ou sublinguale. *Archives de Physiologie Normale et Pathologique*, 10, 141-197.
- Tavill, M. A., Poje, C. P., Wetmare, R. F., & Faro, S. H. (1995). Plunging ranulas in children. *Annals of Otolaryngology & Rhinology*, 104(5), 405-408. <https://doi.org/10.1177/000348949510400512>
- Thompson, J. E. (1920). The relationship between ranula and branchio-genetic cysts. *Annals of Surgery*, 72(2), 164-176. <https://doi.org/10.1097%2F00000658-192008000-00008>
- Turetschek, K., Hospodka, H., & Steiner, E. (1995). Case report: epidermoid cyst of the floor of the mouth: diagnostic imaging by sonography, computed tomography and magnetic resonance imaging. *The British Journal of Radiology*, 68(806), 205-207. <https://doi.org/10.1259/0007-1285-68-806-205>
- Vogl, T. J., Steger, W., Ihrler, S., Ferrera, P., & Grevers, G. (1993). Cystic masses in the floor of the mouth: value of MR imaging in planning surgery. *AJR American Journal of Roentgenology*, 161(1), 183-186. <https://doi.org/10.2214/ajr.161.1.8517299>

von Hippel, R. (1897). Ueber Bau und Wesen der Ranula. *Archiv für klinische Chirurgie*, 55, 164-193.

White, D. K., Davidson, H. C., Harnsberger, H. R., Haller, J., Kamyra, A. (2001). Accessory salivary tissue in the mylohyoid boutonnière: A clinical and radiologic pseudolesion of the oral cavity. *American Journal of Neuroradiology*, 22(2), 406-412. <https://www.ajnr.org/content/22/2/406.short>

Yang, Y., & Hong, K. (2014). Surgical results of the intraoral approach for plunging ranula. *Acta Oto-Laryngologica*, 134(2), 201-205. <https://doi.org/10.3109/00016489.2013.83148>

Funding

Not applicable.

Institutional Review Board Statement

Not applicable.

Informed Consent Statement

Not applicable.

Copyrights

Copyright for this article is retained by the author(s), with first publication rights granted to the journal.

This is an open-access article distributed under the terms and conditions of the Creative Commons Attribution license (<http://creativecommons.org/licenses/by/4.0/>).